

## Thyroid Abscess with Cutaneous Fistula: Case Report and Review of the Literature

Reuben F. De Sousa, MBBS, Amonkar Dilip, MS, FICS,  
and Correia Mervyn, MS

Department of Surgery, Goa Medical College; Goa, India

Contact: Dr. Reuben De Sousa, Room 45, GARD Hostel, Bambolim-Tiswadi-Goa, 403202  
+91-9423810573 reuben\_ds@yahoo.co.in

Received: November 16, 2008  
Accepted: November 21, 2008

**Abstract.** Thyroid abscess arising as a complication of nodular goiter is a rarely documented phenomenon. Acute suppurative thyroiditis is usually associated with pyriform sinus fistula in children, whereas in adults the cause is usually disseminated infection. A good response is noted to drainage and excision with antibiotic cover. We report the case of an adult female who presented with a longstanding multinodular goiter with recent onset of inflammation and a discharging external fistula. The causative organism was *Staphylococcus aureus*. The patient staged an uneventful recovery following hemithyroidectomy with fistulectomy and intravenous antibiotics.

**Keywords.** Multinodular goiter • Thyroid abscess • Thyroiditis

### Introduction

Acute suppurative thyroiditis is an uncommon condition. A review of the literature from the years 1900-to-1980 turned up only 224 cases, the majority of which were reported in children with predisposing factors such as pyriform fistula or thyroglossal duct.<sup>[1]</sup>

Pre-existing thyroid diseases, including longstanding thyroid goiter and thyroid malignancy, are known predisposing factors. Organisms commonly responsible for bacterial thyroiditis are those that typically colonize the skin and oropharynx. However, mycobacteria, fungi, and gram-negative rods have also been documented.<sup>[2]</sup>

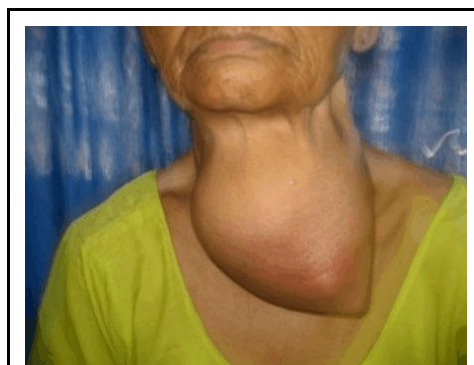Suppurative thyroiditis must be considered in the differential diagnosis of stridor. Untreated cases may lead to septicaemia, osteomyelitis, or septic thrombophlebitis. Early biopsy and cultures are needed for prompt antimicrobial therapy. Surgical drainage is required for large abscesses.<sup>[2]</sup>

We report the case of a 60-year-old female with an endemic multinodular goiter. She presented with acute suppurative thyroiditis and a discharging external fistula along with sick-euthyroid syndrome.

### Case History

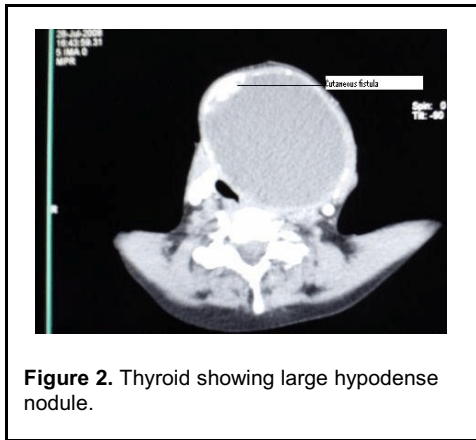
A 60-year-old female (S.D., a farmer by occupation) originally from Uttar Pradesh state of North India was admitted with complaints of a swelling in

the anterior portion of her neck with overlying ulceration. The swelling had been present for the last 33 years, following her first pregnancy, and had since slowly increased in size (see Figure 1). She had a history of palpitations and being easily fatigued. The patient had developed hoarseness of voice and difficulty in swallowing over two months. She said she also had skin discoloration over two months and described rupture of the swelling with purulent discharge for one week. She had no history of neck irradiation, foreign body impaction, respiratory tract infection, or contact with tuberculosis. The patient's sister-in-law was also suffering from a goiter and had a history of dietary intake of iodine-deficient rock salt.



**Figure 1.** Multinodular goiter with a pointing thyroid abscess.

Vitals on admission showed a blood pressure of 130/72 mm Hg, heart rate of 86 beats/min, respiratory rate of 20/min, and oral temperature of 36.7°C (98.06°F). She was thinly built, alert, and appeared uncomfortable. Her thyroid gland was enlarged to a dimension of 16 x 15 cm. It had a 1 x 1 cm overlying ulcer on the upper left side with purulent discharge. The left side of the gland was predominantly enlarged, tense, tender and cystic, without bruit, pushing the trachea to the right. The skin that overlay the goiter was erythematous, but no engorged veins or lymphadenopathy was present. Swallowing exacerbated her pain. Her sleeping pulse rate was normal (70 beats/min). Deep tendon reflexes were slowed and no tremors were present.



**Figure 2.** Thyroid showing large hypodense nodule.

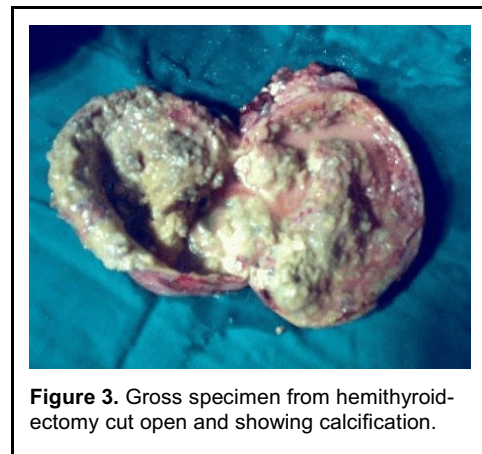
Figure 2 is a thyroid CT scan showing a large hypodense nodule with peripheral enhancement and cutaneous fistula. Laboratory studies showed hemoglobin of 11.5 g/dL, white blood cell count of 8900/ $\mu$ L, and erythrocyte sedimentation rate of 35mm/hour. Thyroid function tests showed low  $T_3$  (<5.0 ng/dL), low  $T_4$  (<3.0  $\mu$ g/dL), and a reference range TSH (3.6  $\mu$ U/mL), suggestive of euthyroid sick syndrome. ECG revealed left bundle branch block and poor R wave progression. X-ray of the soft tissues of the neck showed tracheal compression by a homogenous soft tissue density pushing it to the right. The retropharyngeal space was normal.

Thyroid ultrasonography revealed that the left lobe of the thyroid gland was enlarged. The lobe had multiple enlarged cystic lesions with dense internal echoes and a peripheral rim of coarse calcification. CT scan of the neck and thorax showed that the left lobe of the gland was replaced by multiple nodules. The largest nodule measured 9 x 10 x 9.3 cm, with peripheral rim enhancement and foci of coarse calci-

fications in the wall. The patient's trachea was deviated to the right. Indirect laryngoscopy was normal with no evidence of pyriform sinus or cord abnormalities. Needle aspiration yielded yellow-brown pus—hence the patient was commenced on broad spectrum antibiotics and IV fluids and scheduled for surgery.

The enlargement of the left lobe of the gland was 15 x 15 cm and was, again, cystic in consistency. The overlying ulcerated skin was excised *in toto*. The cyst was incised and about 500 mL of purulent fluid was drained. Following this, left hemithyroidectomy was performed.

Figure 3 shows a gross specimen of hemithyroidectomy (cut open) with areas of calcification. In view of the tracheal compression, delayed extubation was performed after 24 hours. The patient was conscious and afebrile on post-op day one and was breathing room air. She staged an uneventful recovery and was discharged on post-op day five.



**Figure 3.** Gross specimen from hemithyroidectomy cut open and showing calcification.

Pus culture showed methicillin-resistant *Staphylococcus aureus* sensitive to vancomycin and teicoplanin. Histopathology of the abscess wall revealed dense fibrous tissue, necrosis, cholesterol clefts, and foreign body giant cells with spindle cells in areas of fibrosis. The surrounding thyroid gland showed colloid goiter. Due to the large areas of necrosis and spindle cells, immunohistochemistry was performed to rule out anaplastic carcinoma; tests for thyroglobulin and cytokeratin were negative.

At one month post-op, the patient had a healthy scar with no noticeable complications. Hoarseness and dysphagia had resolved and thyroid function tests showed reference range values: her  $T_3$  was 86.0 ng/dL,  $T_4$  was 5.62  $\mu$ g/dL, and her TSH was 6.97

μU/mL. The patient did not require thyroxine or calcium supplementation.

## Discussion

Thyroid abscess and acute suppurative thyroiditis are not common, representing only 0.1%-to-0.7% of surgically treated thyroid pathologies.<sup>[3]</sup> More common in children than adults, these rarities are associated with poorly indicative clinical symptoms, thus making diagnosis difficult. In a literature review in 1981, Schweitzer and Olson noted that only 39 cases of thyroid abscess had been reported in the medical literature since 1950. Of the 39 cases of abscess, 16 were in children.<sup>[4]</sup>

Infections of the thyroid gland are rare due to its isolated anatomic location, fibrous capsule, rich blood supply, generous lymphatic drainage, and high content of iodine. An infection may result from hematogenous or lymphatic seeding, or may spread directly from the oropharynx, contiguous cervical tissue, esophageal perforation, foreign bodies, or patent thyroglossal fistula.<sup>[2]</sup>

More than two-thirds of the women and half of the men with acute suppurative thyroiditis have pre-existing thyroid disease.<sup>[5]</sup> In a study by Nmadu in Nigeria, 14 of 17 cases of thyroid abscess had pre-existing multinodular goiter.<sup>[6]</sup> In another study by Nmadu, Ameh, and Sabo in Zaria-Nigeria, the incidence of thyroid abscess developing in endemic multinodular goiter was 10.7% over ten years (9 of 84 cases).<sup>[7]</sup>

In 1978, Takai et al. reported 15 patients with acute suppurative thyroiditis in whom a pyriform sinus fistula was the apparent source of infection.<sup>[8]</sup> The fistula originates from the pyriform sinus, and ends blindly in the parenchyma of the thyroid gland or in the perithyroid soft tissue. The fistula tends to become infected after a bout of upper respiratory tract infection that is attributed to the accumulation of contaminated secretions in the pharynx and fistulous tract. Presentation is usually as a left-sided neck mass which can cause overlying skin erythema as it enlarges. After diagnosis by barium esophagography and computed tomography, treatment involves antibiotics, drainage, and fistulectomy.<sup>[9]</sup>

The most important causal organisms are *Staphylococcus aureus*, *Streptococcus* species, and anaerobes. These infections account for approximately 70% of cases.<sup>[10]</sup> Other causes include *Escherichia coli* following urosepsis,<sup>[2][10]</sup> *Bacteroides fragilis* in

post-hysterectomy,<sup>[11]</sup> *Klebsiella*, *Salmonella typhi*, *Salmonella brandenburg*, *Eikenella corrodens*, *Fusobacterium mortiferum*,<sup>[12]</sup> and aspergillosis.<sup>[13]</sup> Rare cases have been reported from Lemierre's syndrome<sup>[14]</sup> (post-anginal septicaemia due to anaerobes) and infectious mononucleosis in adolescence<sup>[15]</sup> presenting with thyroid abscess.

Acute suppurative thyroiditis responds well to intravenous antibiotics with or without incision and drainage of the abscess. The condition rarely causes an external fistula.<sup>[8]</sup> In our case, a decision to perform a partial thyroidectomy was made in view of a large abscess in the left lobe which must have burst through the perithyroidal tissues to involve the skin. The external fistula was treated by fistulectomy and primary closure. The patient's dysphagia and hoarseness of voice improved rapidly following the surgery, and the euthyroid sick syndrome rapidly resolved postop.

In conclusion, acute suppurative thyroiditis is a little known complication of multinodular goiter. It usually results from concomitant sepsis or anatomic abnormality such as pyriform sinus. Management must integrate the treatment for possible abnormal thyroid status with the treatment of sepsis and removal of the causative anomaly.

## References

1. Yu, E.H., Ko, W.C., Chuang, Y.C., et al.: Suppurative *Acinetobacter baumannii* thyroiditis with bacteremic pneumonia: case report and review. *Clin. Infect. Dis.*, 27(5):1286-1290, 1998.
2. Deshmukh, H.G., Verma, A., Siegel, L.B., et al.: Stridor, the presenting symptom of a thyroid abscess. *Postgrad. Med. J.*, 70, 847-850, 1994.
3. Menegaux, F., Biro, G., Schatz, C., et al.: Thyroid abscess: Apropos of 5 cases. *Ann. Med. Interne.*, (Paris), 142(2):99-102, 1991.
4. Schweitzer, V.G. and Olson, N.R.: Thyroid abscess. *Otolaryngol. Head Neck Surg.*, 89(2):226-229, 1981.
5. Farwell, A.P. and Braverman, L.E.: Inflammatory thyroid disorders. *Otolaryngol. Clin. North Am.*, 29(4): 541-556, 1996.
6. Nmadu, P.T.: Infective thyroiditis in northern Nigeria: a fifteen year study. *East Afr. Med. J.*, 66(11):748-751, 1989.
7. Ameh, E.A., Sabo, S.Y., and Nmadu, P.T.: The risk of infective thyroiditis in nodular goiters. *East Afr. Med. J.*, 75(7):425-427, 1998.
8. Rohondia, O.S., Koti, R.S., Majumdar, P.P., et al.: Thyroid abscess. *J. Postgrad. Med.*, 41(2):52-54, 1995.

9. Gan, Y. and Lam, S.L.: Imaging findings in acute neck infection due to pyriform sinus fistula. *Ann. Acad. Med. Singapore*, 33:636-640, 2004.
10. Sicilia, V. and Mezitis, S.: A case of acute suppurative thyroiditis complicated by thyrotoxicosis. *J. Endocrinol. Invest.*, 29:997-1000, 2006.
11. Yeluri, S., Mehta, J.P., Karanth, S., et al.: A tender lump in the neck. *M.J.A.*, 184(3):137, 2006.
12. Stavreas, N.P., Amanatidou, C.D., Hatzimanolis, E.G., et al.: Thyroid abscess due to a mixed anaerobic infection with *Fusobacterium mortiferum*. *J. Clin. Microbiol.*, 43(12):6202-6204, 2005.
13. Lisbona, R., Lacourciere, Y., and Rosenthal, L.: Aspergillomatous abscesses of the brain and thyroid. *J. Nuc. Med.*, 14(7):541-542, 1973.
14. Kara, E., Sakarya, A., Keles, C., et al.: Case of Lemierre's syndrome presenting with thyroid abscess. *Eur. J. Clin. Microbiol. Infect. Dis.*, 23(7):570-572, 2004.
15. Astl, J., Kuchynkova, Z., Taudy, M., et al.: Thyroid abscess at an adolescent age. *Int. J. Pediatr. Otorhinolaryngol.*, 67(12):1375-1378, 2003.